



PATIENT

Mae Mae Norton

SPECIES

Canine

BREED

Mixed

SEX

FS

AGE

2 years

WEIGHT

9.4 kg

INTERPRETED BY

Remo Lobetti, BVSc,
MMedVet (Med), PhD,
Dipl. ECVIM

IMAGING PERFORMED BY

Brent Crutchfield, DVM

HOSPITAL NAME

Treasure Coast Animal
Emergency

REFERRING VET

Angela Cail

INVOICE

304027

DATE

3/17/23

PRESENTING CLINICAL SIGNS

History: Dietary allergies.

Physical Examination: N/A.

Urinalysis: N/A.

CBC: N/A

Serum Biochemistry: N/A.

Radiographic Findings: N/A

ULTRASONOGRAPHIC EXAMINATION OF THE ABDOMEN

Urinary System

Full urinary bladder with a normal thickness (0.1 cm) and appearance of the wall. Normal anechoic urine with no sediment or uroliths evident.

Normal trigone area, proximal urethra, and iliac blood vessels.

Normal iliac lymph nodes (1.6 cm). Ureters not visualized.

Normal renal size (left 4.2 cm, right 4.6 cm), echogenic appearance, cortico-medullary differentiation, pelvis, and capsule.

Reproductive System

N/A.

Adrenal Glands

Normal shape, echogenic appearance, and position but small in size. Left 0.33 cm, right 0.38 cm.

Spleen

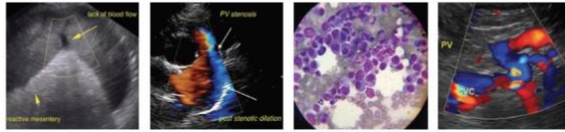
Normal size and echogenic appearance. Smooth homogenous parenchyma, regular curvilinear capsule, and normal vasculature. No evidence of inflammatory, neoplastic, infarction, or infiltrative changes noted.

Liver

Normal size, echogenic appearance, portal markings, and regular curvilinear capsule. No nodules or masses evident.

Gall bladder

Full bladder containing normal anechoic bile. Normal thickness (0.1 cm) and echogenic appearance of the wall. Normal bile duct.



PATIENT

Mae Mae Norton

SPECIES

Canine

BREED

Mixed

SEX

FS

AGE

2 years

WEIGHT

9.4 kg

INTERPRETED BY

Remo Lobetti, BVSc,
MMedVet (Med), PhD,
Dipl. ECVIM

IMAGING PERFORMED BY

Brent Crutchfield, DVM

HOSPITAL NAME

Treasure Coast Animal
Emergency

REFERRING VET

Angela Cail

INVOICE

304027

DATE

3/17/23

Gastrointestinal

Normal appearance of the stomach, duodenum, small intestine, ileo-cecal junction, and colon with no loss of layering, normal wall thickness (stomach 0.41 cm, duodenum 0.48 cm, jejunum 0.39 cm, colon 0.1 cm) and peristaltic activity, and no distension of the lumen.

Pancreas

Normal size and echogenic appearance. Regular capsule. Normal echogenic appearance of the mesentery and fat surrounding the pancreas.

Free Abdomen

No mesenteric lymphadenomegaly.
No ascites evident.

ULTRASONOGRAPHIC FINDINGS

Primary findings:

- None.

Secondary findings:

- None.

INTERPRETATION OF THE FINDINGS & FURTHER RECOMMENDATIONS

Normal ultrasound examination of the abdomen.

Although the small adrenal glands are most likely incidental and normal for this patient, Addison's disease should be considered and excluded by a basal cortisol assay or ACTH stimulation test.

The information and recommendations provided are based on the images presented by the referring veterinarian. No evaluation can be communicated regarding pathology that was not visible in the image/video clips provided.

Thank you for this referral. If the clinical or image interpretation does not parallel your findings or if I can be of any further assistance please contact me.

Remo Lobetti, BVSc, MMedVet (Med), PhD, Dipl. ECVIM (Internal Medicine)

rlobetti@mweb.co.za